Functional neuroanatomy the visceral nervous system (ANS)

Chris Thomson
BVSc(Hons), Dip ACVIM (Neurol), Dip ECVN, PhD
Associate Professor Neurobiology,
Dept. of Vet. Med.,
University of Alaska, Fairbanks,
Alaska.

How do you evaluate the ANS in your neurological examination?

Visceral Nervous System

- Visceral efferent and afferent system
- Visceral afferent system
  - Receptors
    - GVA – pressure, stretch and chemical changes (pH, O_2, CO_2)
    - SVA – taste, olfaction
    - Not tactile/touch

      e.g. C-section in a cow
  - Single neuron with peripheral ganglion
  - Axons – cranial and spinal nerves
    - CNN ganglia
      - geniculate (VII),
      - distal ganglia CN IX (petrosal)
      - distal ganglion CN X (nodose)
    - Spinal ganglia
    - Use same pathways as the visceral efferent nerves
    - Spinoreticular and spinothalamic tracts

http://4.bp.blogspot.com

Visceral afferent system

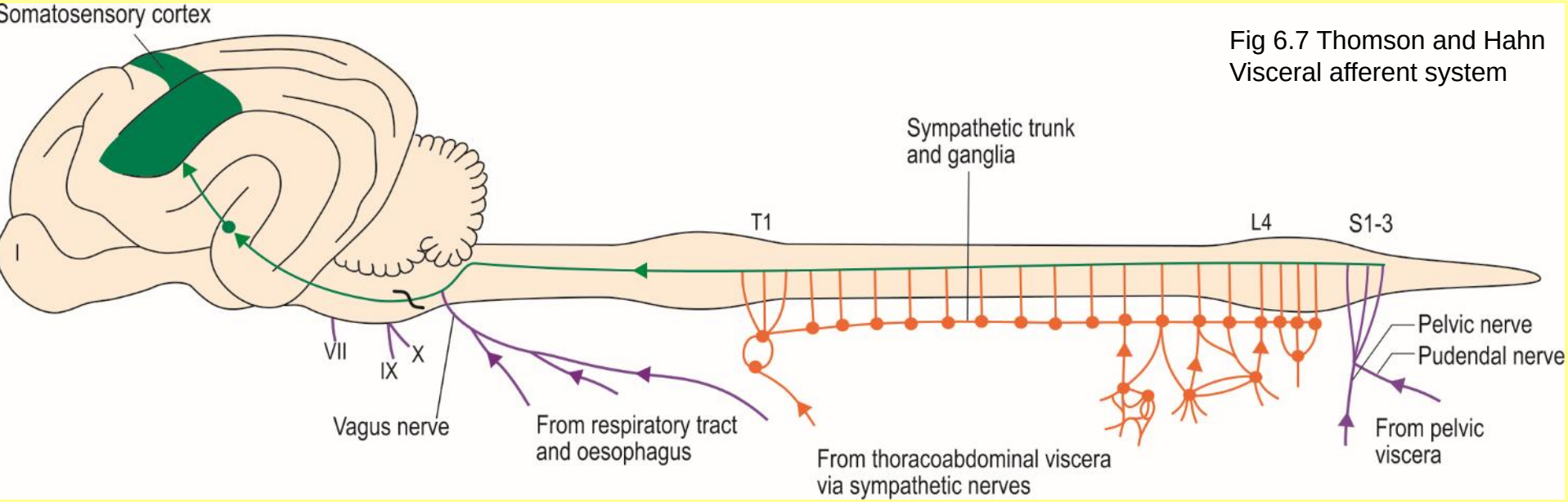

Fig 6.7 Thomson and Hahn
Visceral afferent system

- Input via cranial nerves
  - CN I – Olfaction SVA
  - Solitary nucleus (CN VII, IX, X)
    - » Taste – CNN VII and IX (also known as gustatory nucleus)
    - » Viscera (thoracic and abdominal), baroreceptors, chemoreceptors – CNN IX and X
      - » CN X – 80% of fibres are visceral afferents
    - » Output from solitary nucleus for reflex function via reticular formation
      - » e.g. respiratory, CVS, swallowing, micturition
    - » Conscious perception – solitarothalamic tract
- Input via spinal nerves
  - Reflexes – sympathetic or parasympathetic
    - » e.g. tachy- or bradycardia
  - Conscious perception via spinoreticular tract to thalamus

Visceral efferent system (ANS)

- Autonomic nervous system ANS
  - Purely efferent system
  - To smooth and cardiac muscle, and glands
  - Two functional components
    - Differentiated morphologically, pharmacologically and physiologically
    - Parasympathetic NS
      - Housekeeping system ‘rest and digest’
    - Sympathetic NS
      - Prepares the body for flight or to fight
  - Dual innervation all body systems

http://staffsites.slcschools.org/

Anatomy of the ANS

- Central nervous system (CNS) components
  - Brain
    - Forebrain (diencephalon – UMN to ANS)
    - Brainstem –
      - UMN cardiac and respiratory and protective centres
      - LMN in CNN
        - » Naming of CNN nuclei: parasympathetic nucleus of CN___
  - Spinal cord
    - Thoracic, lumbar, sacral
- Peripheral nervous system (PNS)
  - Cranial and spinal nerves
  - 2 neuron system with peripheral ganglia
    - (c/w visceral afferent – single neuron with peripheral ganglion)

Anatomical concepts of the ANS

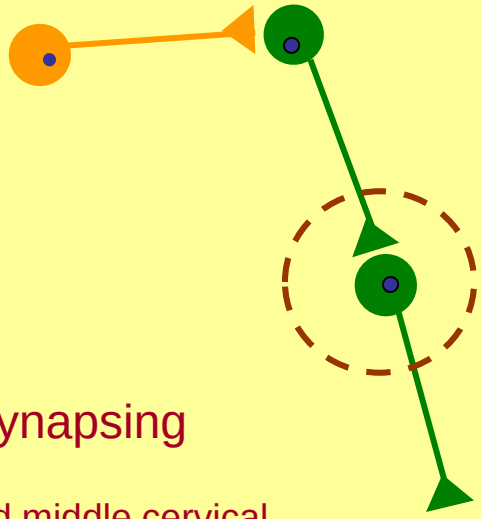

- How many neurons?
  - One CNS neuron
    - Brain or spinal cord
  - Two neurons in the PNS
    - 1st neuron cell body in CNS
    - 2nd neuron cell body in ganglion
    - May pass through several ganglia without synapsing
      - e.g. sympathetic supply to head
        - » T1-3 spinal cord, through cervicothoracic and middle cervical ganglion, synapses in cranial cervical ganglion
  - Terminology – pre and post synaptic neurons
- Where do ANS fibres leave CNS?
  - Parasympathetic NS = craniosacral NS
  - Sympathetic NS = thoracolumbar NS

Central controls for VNS

- Hypothalamus
- Central regulator
  - Receives input
    - From viscera
      - Via CN VII, IX and X
        - » To nucleus solitarius in myelencephalon
        - » spinothalamic tract with input from segmental spinal nerves
      - From telencephalon
        - » Emotional input
  - Output
    - Neural – via brainstem and spinal cord
    - Humoral – via hypophysis

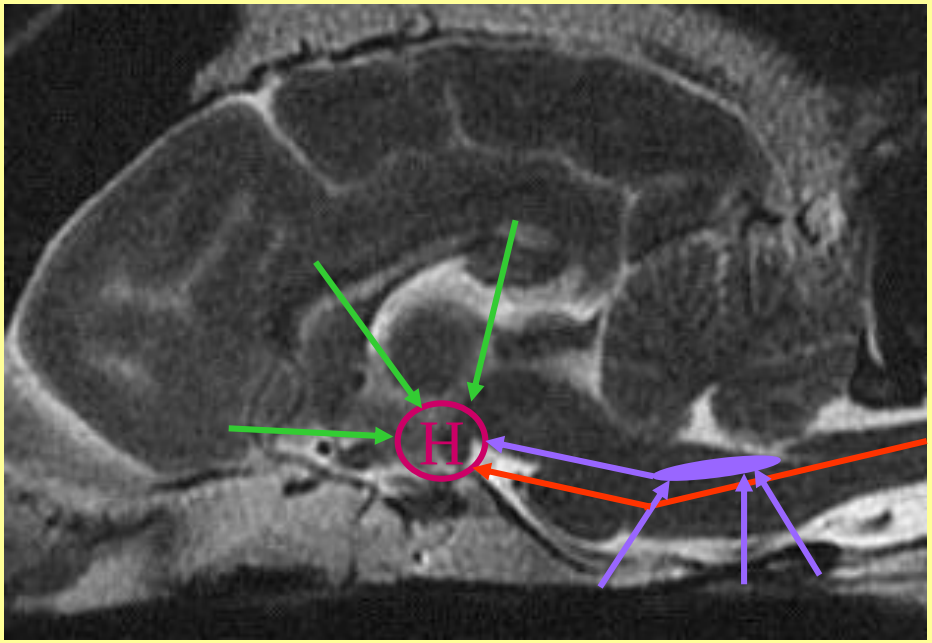

Clinical correlate: damage to hypothalamus can lead to autonomic imbalance such as excess or insufficient sympathetic function

Fergus 1.5yo MN Cocker Spaniel
Hx: 3wk blindness and dysuria

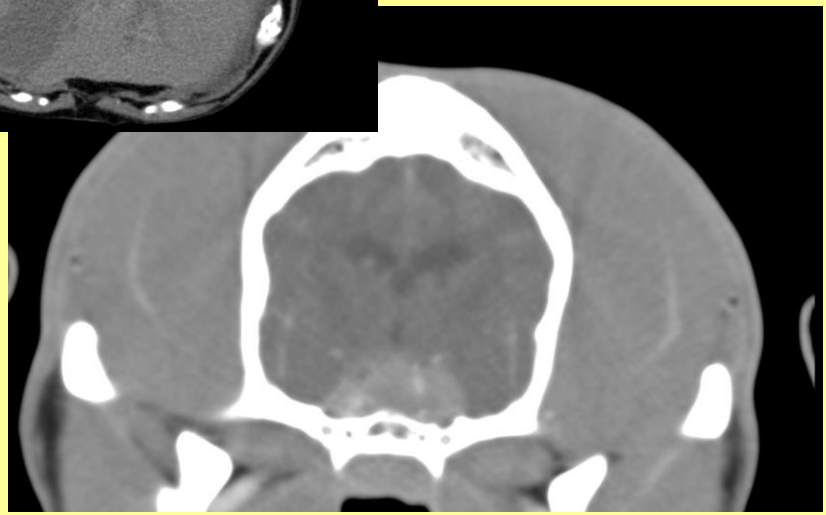

Reticular visceral control centres

- Medulla oblongata (myelencephalon)
  - Respiratory centre
    - Afferents – PaO_2 and $PaCO_2$ chemoreceptors, aortic and carotid bodies, input to solitary nucleus,
    - Efferent – medullary reticulospinal tract to respiratory muscles
  - Cardiovascular centre
    - Afferents – blood pressure baroreceptors, aortic and carotid sinus, to solitary nucleus
    - Efferents – medullary reticulospinal tract to intermediate horn and sympathetic outflow
  - Vomiting centre
    - Coordination visceral and somatic nervous systems
    - Afferents – stomach and small intestine (chemo and mechanoreceptors), forebrain, vestibular, solitary n. and chemoreceptor trigger zone (area postrema near obex; outside blood brain barrier)
    - Efferents to glossopharyngeal, hypoglossal and parasympathetic nucleus of X, reticulospinal tract (trunk muscles)
  - Swallowing
    - Afferents – to sensory nucleus of V
    - Efferents – nucleus ambiguus
  - Coughing
- Pons
  - Micturition centre
    - Reticulospinal efferents to sacral cord

Dog MRI, transverse caudal myelencephalon

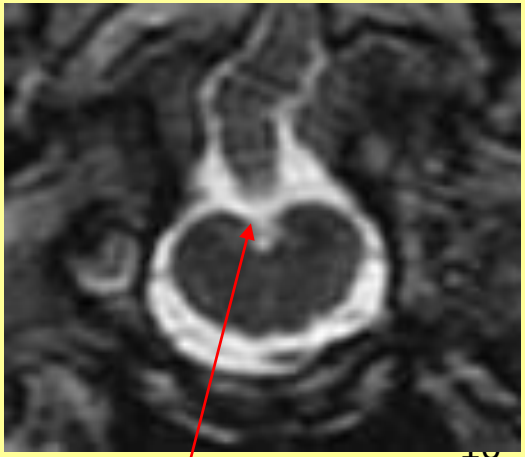

Area postrema

Brainstem compression

- Loss of cardiopulmonary UMN function
- Altered respiratory pattern

- Raised ICP

  → Cerebral ischaemic response

  → Catecholamine surge to maintain cerebral perfusion pressure

  → Cushing reflex bradycardia

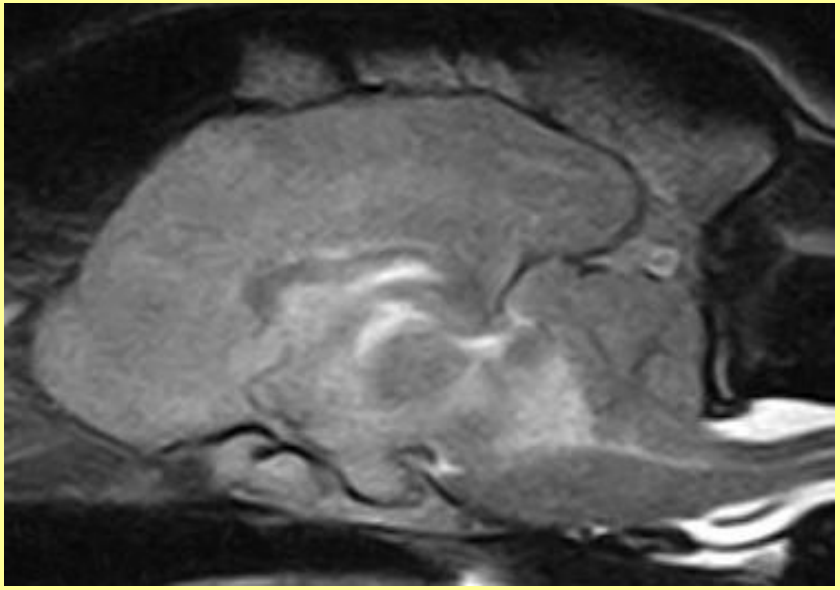

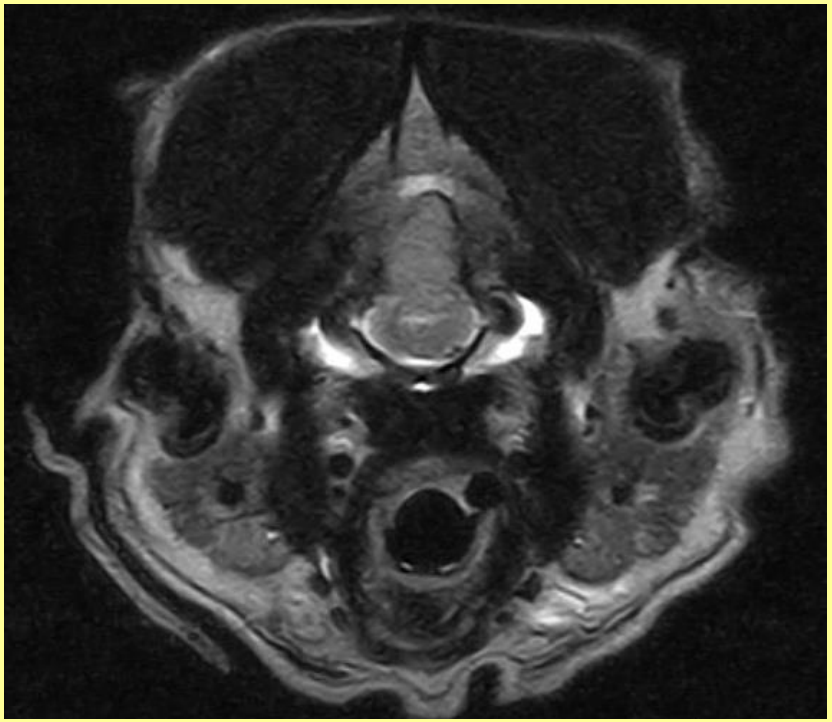

Bates: 4yo MN Sp Spaniel
Hx seizures,
Tetraparesis, stupor, proprioceptive deficits

Peripheral components of the ANS

- 2 x LMN + ganglion
- Location of ganglion PS vs Symp
- Neurotransmitter

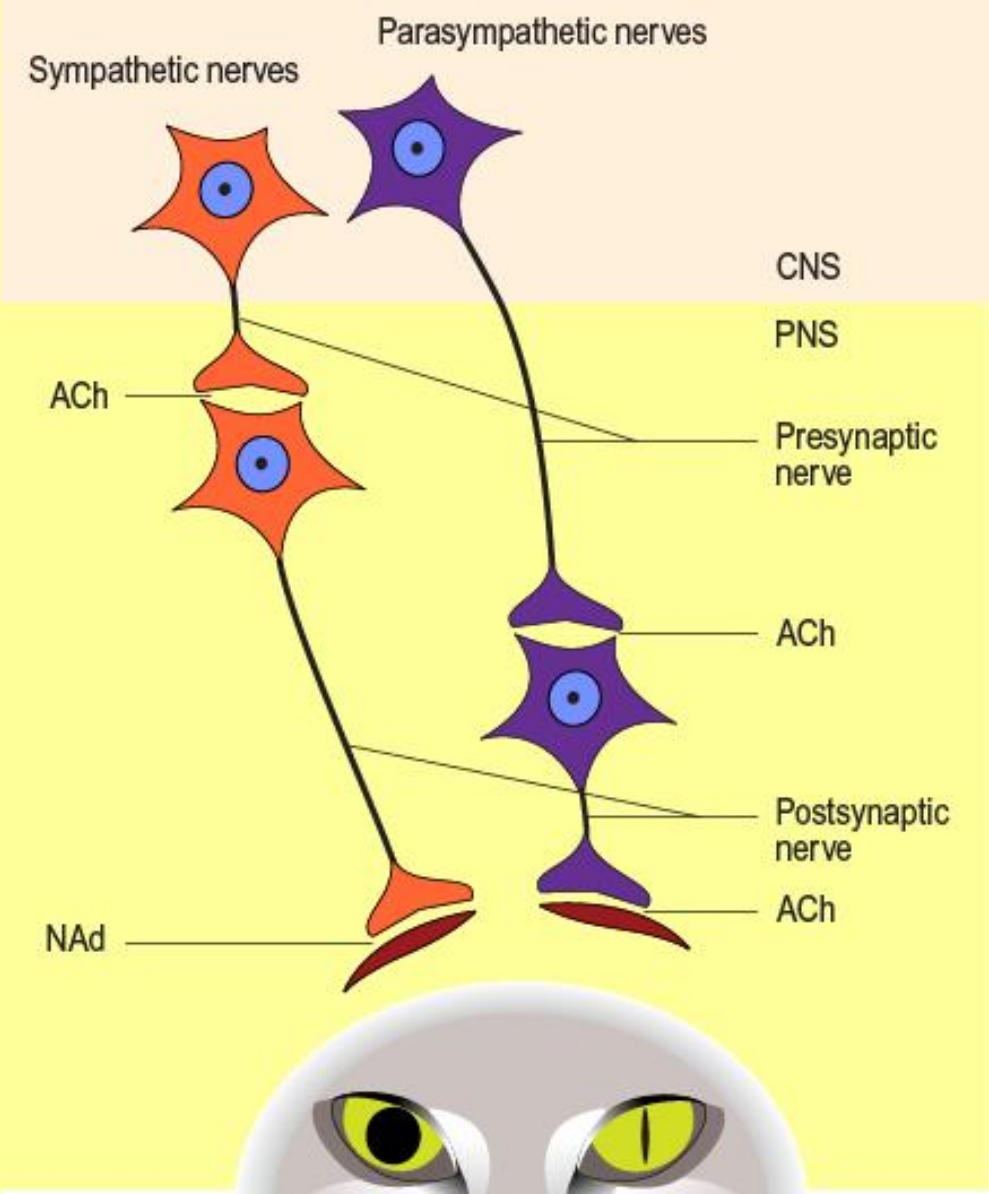

Fig 12.2 Thomson and Hahn

ANS

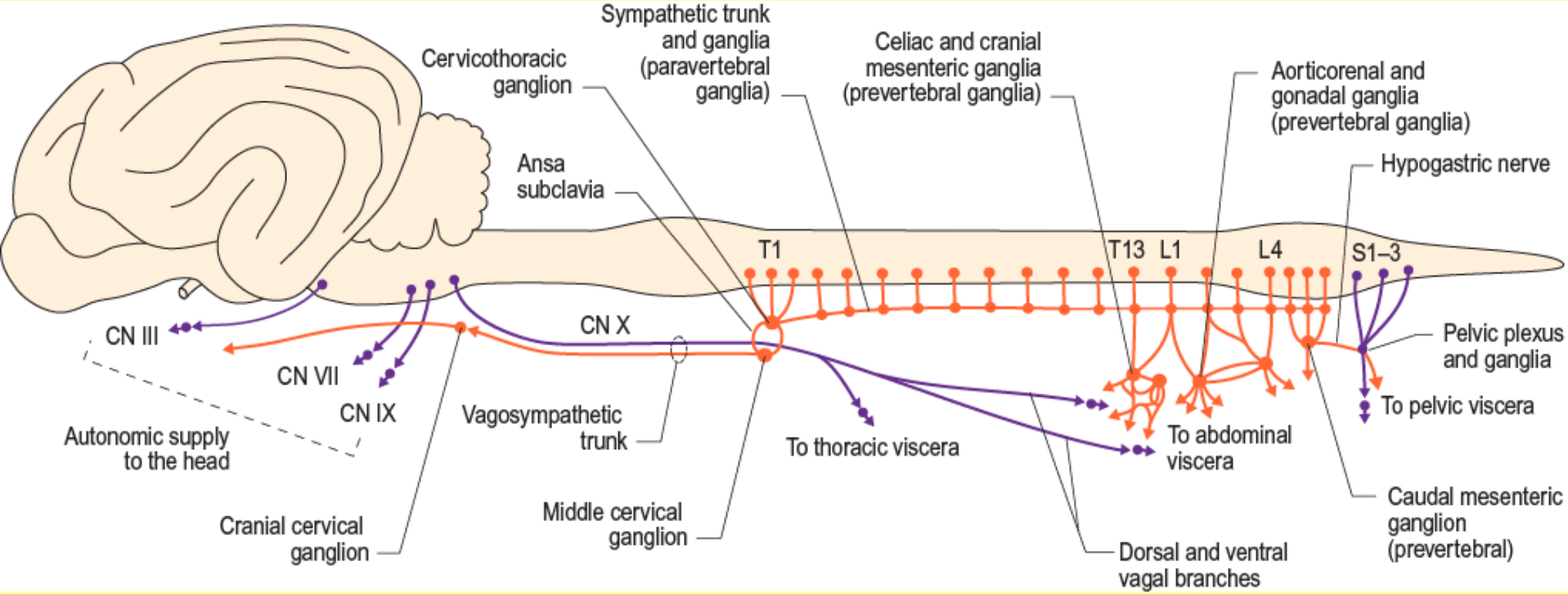

Fig 12.1 Thomson and Hahn, ANS

Sympathetic innervation of viscera

- Thoracolumbar outflow from CNS
  - C8/T1 to L4/5
  - Thoracic cavity
    - Sympathetic chain of nerves and paravertebral ganglia
  - Abdominal and pelvic cavities
    - Fusion of fibres to form prevertebral ganglia
      - e.g. celic, cranial and caudal mesenteric ganglia
  - Head
    - Supplied by spinal nerves from T1-3 (C8-T5)
    - Via vagosympathetic trunk

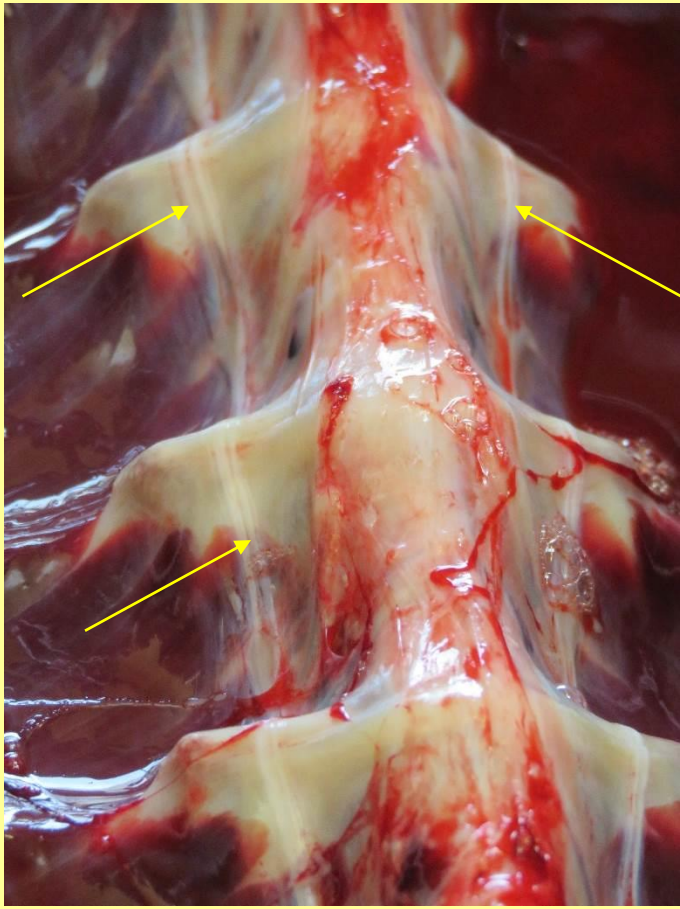

Sympathetic chain, harbor seal
Ventral aspect thoracic vertebral column

Sympathetic trunk and ganglia

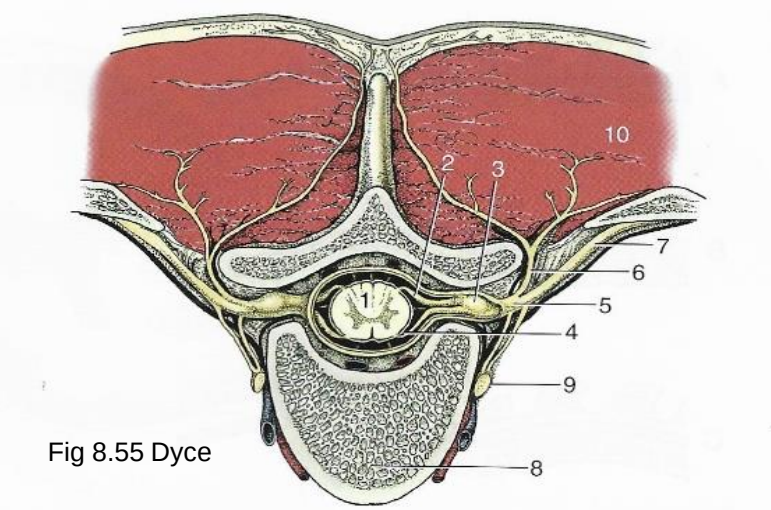

Fig 8.55 Dyce

Figure 8–55 Transection of the vertebral column to show the formation of a spinal nerve. *1,* Spinal cord; *2,* dorsal root; *3,* spinal ganglion; *4,* ventral root; *5,* spinal nerve; *6,* dorsal branch of spinal nerve; *7,* ventral branch of spinal nerve; *8,* body of vertebra; *9,* sympathetic trunk; *10,* epaxial muscles.

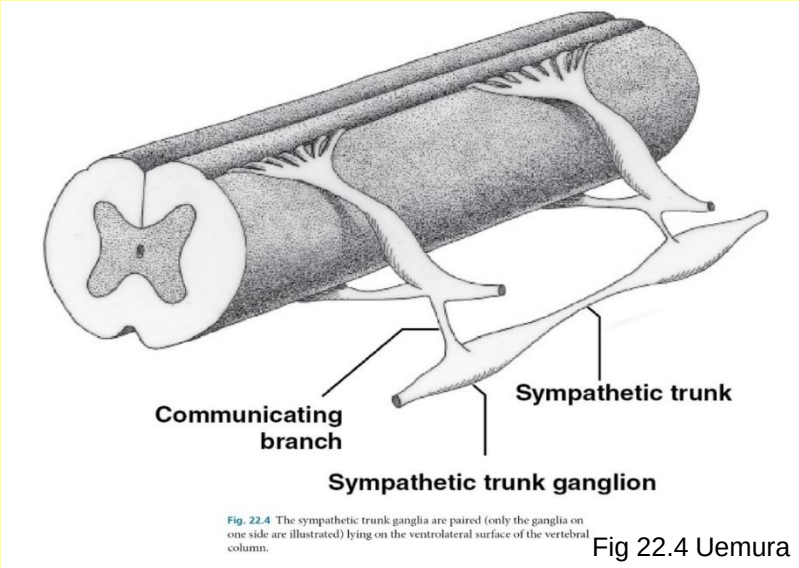

Fig. 22.4 The sympathetic trunk ganglia are paired (only the ganglia on one side are illustrated) lying on the ventrolateral surface of the vertebral column.

Fig 22.4 Uemura

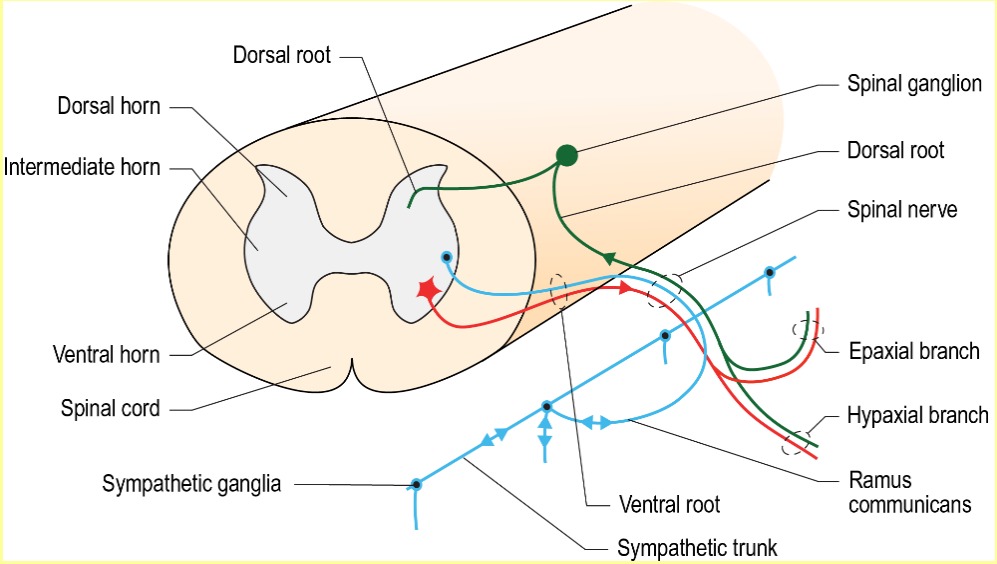

Thomson and Hahn, fig 12-3

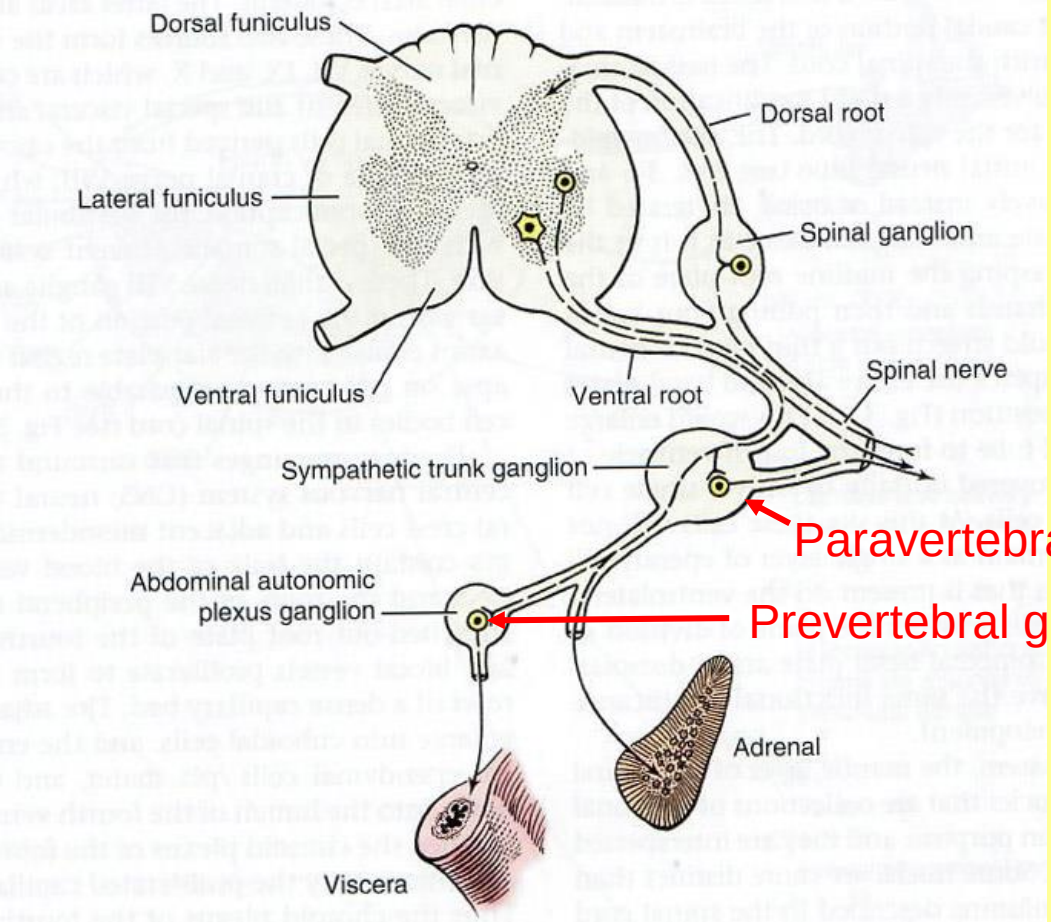

Fig 3.8 deLahunta and Glass

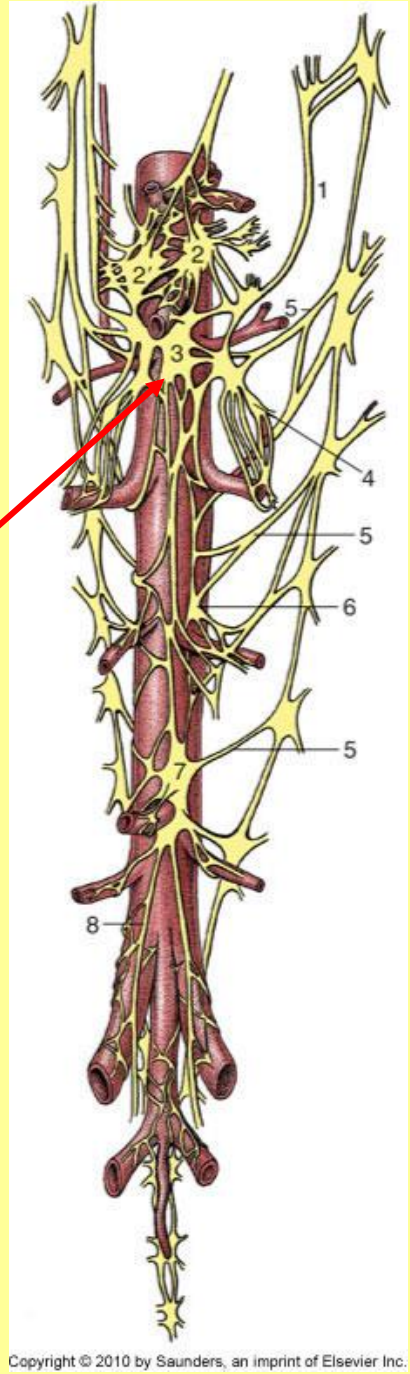

Fig 8.76 Dyce

Autonomic innervation of the eye

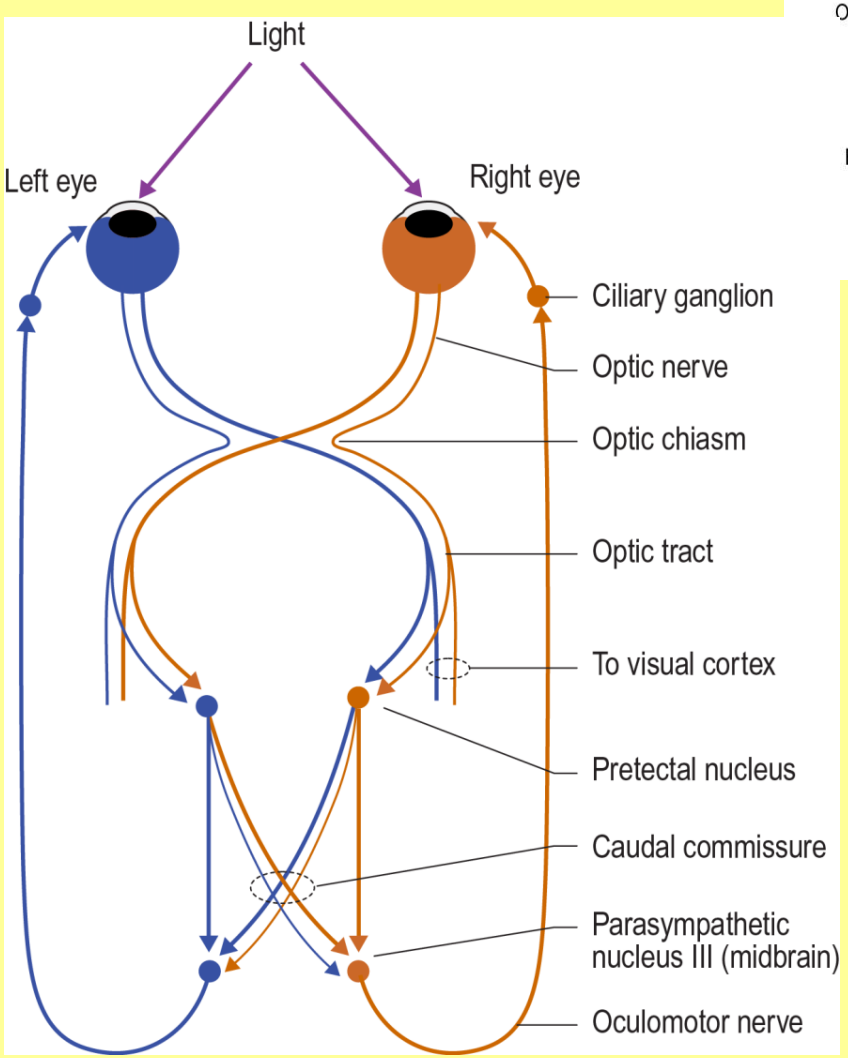

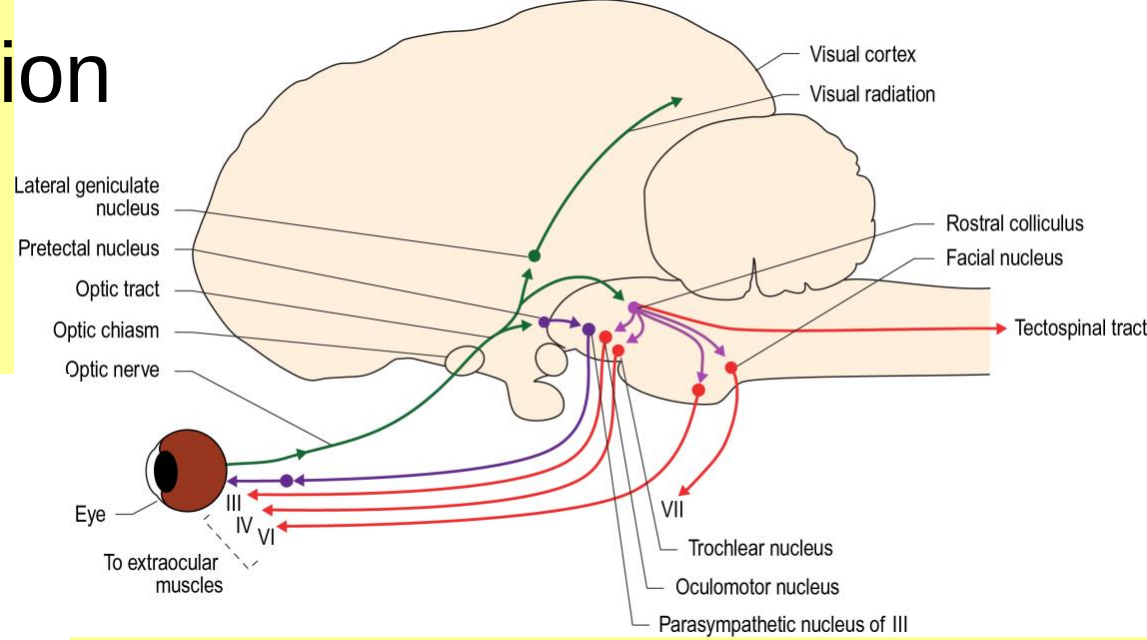

Figs 10.8 and 9 Thomson and Hahn, Pupillary light reflex

Pupillary light reflex

- What CNN?
- Signs of dysfunction
  - Afferent lesion
    - Other signs?
  - Efferent lesion
    - Other signs?

Regarding pupillary constriction in birds, is it only parasympathetic innervation?



Ref: Clippinger et al, Avian Neuro Exam, Vet Clin Exot Anim 10, 2007

Pupillary dysfunction

- In acute brain disease
  - Miosis
    - Compression of mesencephalon
    - Mechanism?
      - Parasympathetic nucleus of CN III
        - » facilitation or loss of forebrain inhibition?
      - Loss of sympathetic function?
  - Mydriasis
    - Loss of parasympathetic nucleus of CN III function

Cat found unconscious by road

Fig 12.6 Thomson and Hahn

Fig 7-13 deLahunta and Glass
Ruminants: smaller palpebral fissure, hyperthermia, loss of Ipsilateral nasal planum sweating

Thoracolumbar lesion in alpaca, courtesy Dr. Caroline Hahn

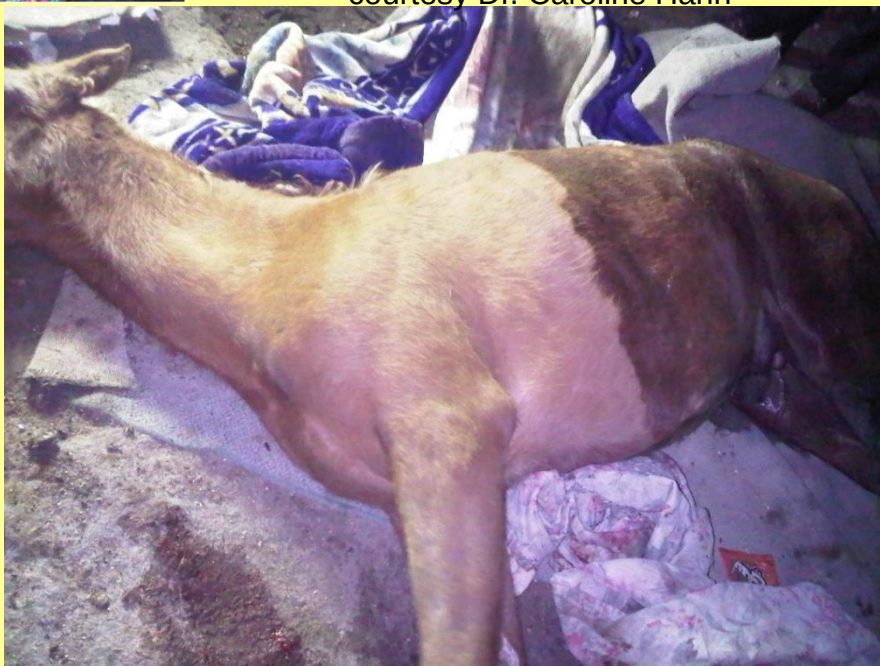

Lesion classification for Horner's syndrome

1st order – brain and spinal cord pathway

2nd order – presynaptic neuron

3rd order – post synaptic neuron

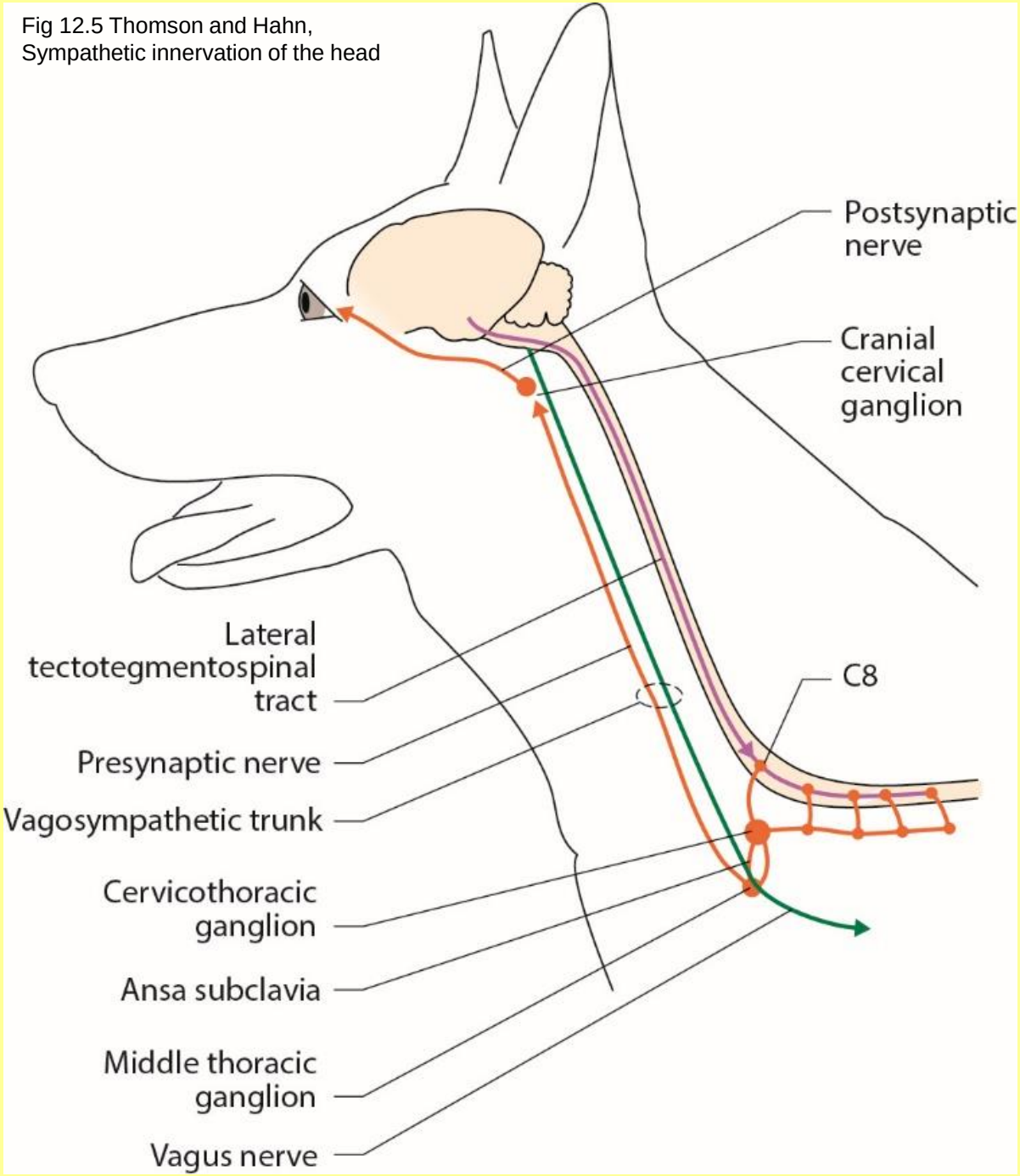

Fig 12.5 Thomson and Hahn, Sympathetic innervation of the head

Dysfunction in pupil innervation

- Which has a more favourable prognosis?
- Why?

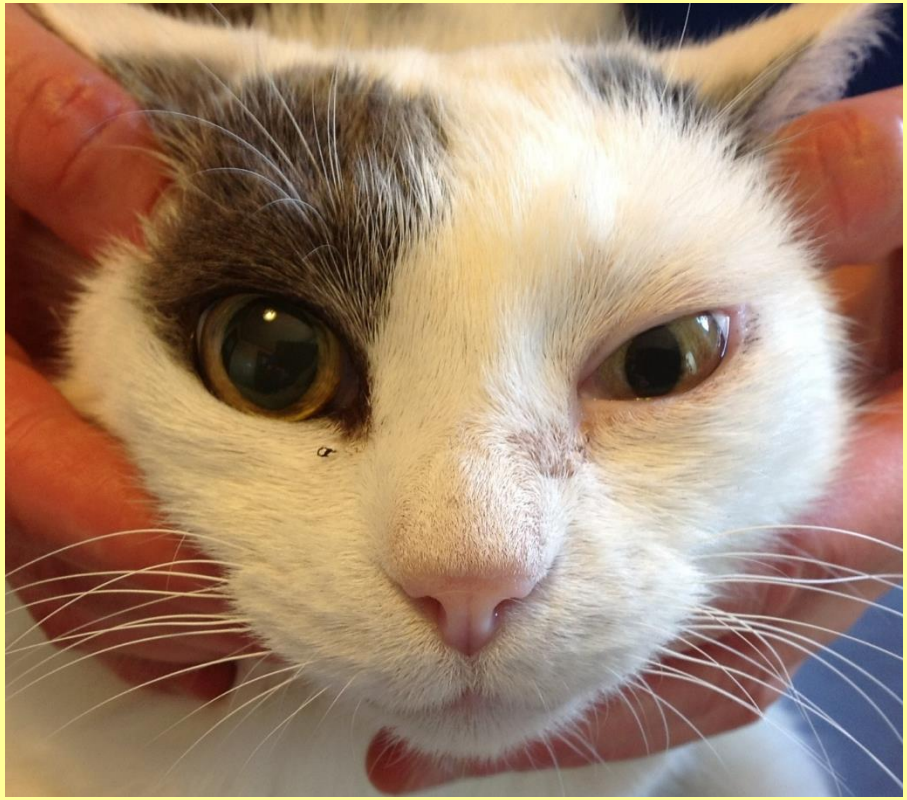

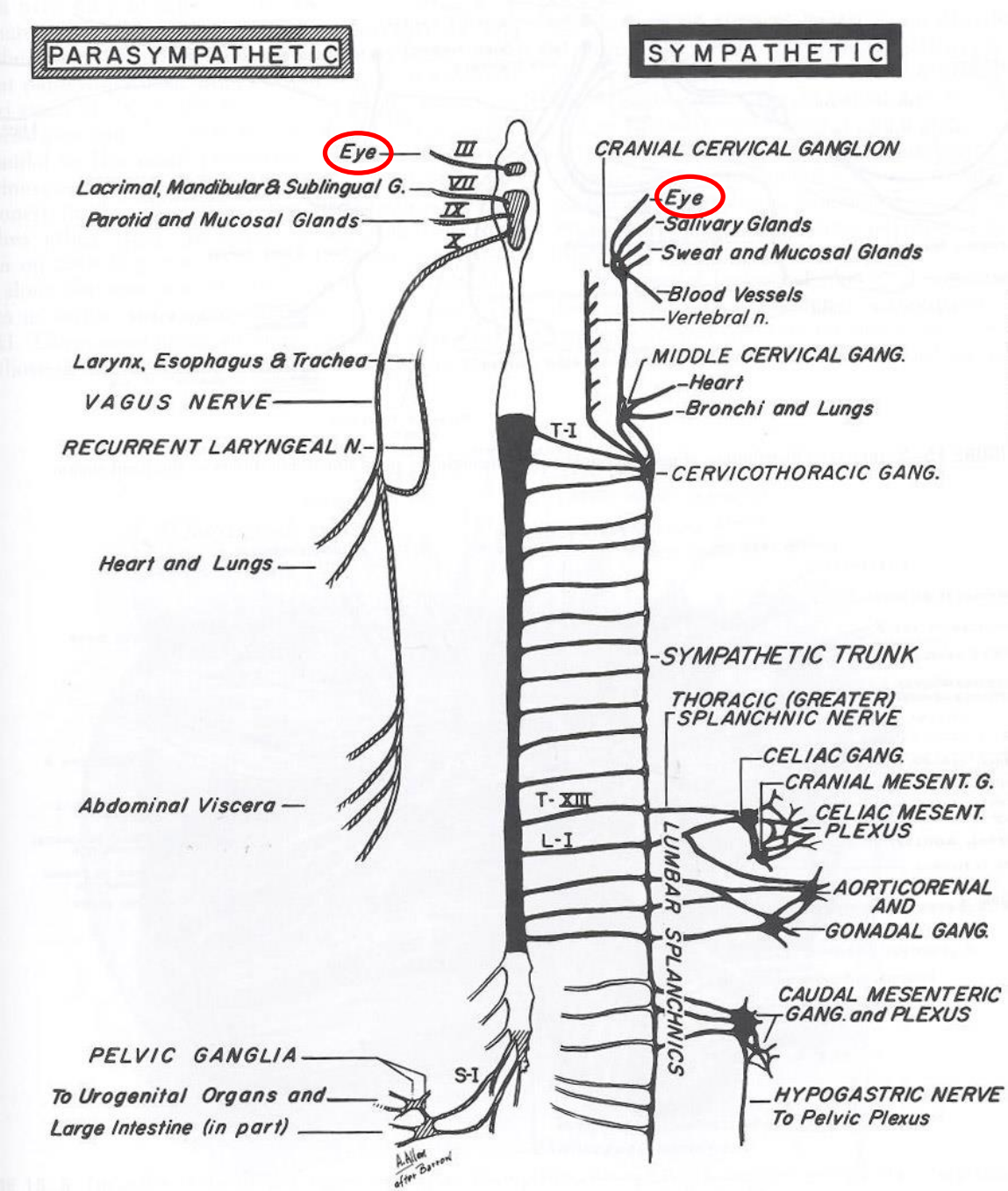

Evans figure 15-2



Distance penlight test: for subtle anisocoria and strabismus

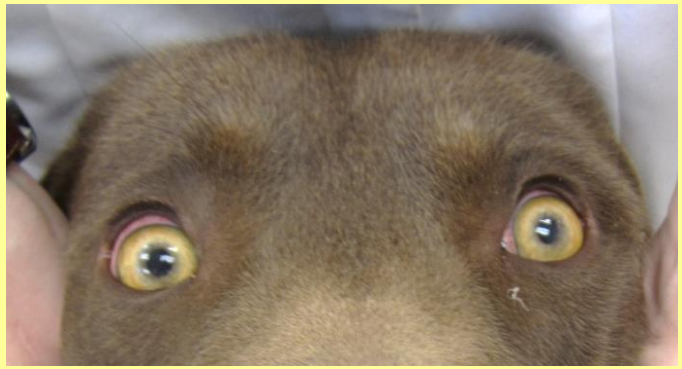

Localising the lesion causing pupil dysfunction

- Other neurological signs
- Pharmacological testing
  - Presynaptic neuron damage
    - Post synaptic neuron and NMJ intact
  - Post synaptic neuron damage
    - loss of post-synaptic neuron and NMJ
    - smooth muscle is hypersensitive to neurotransmitter

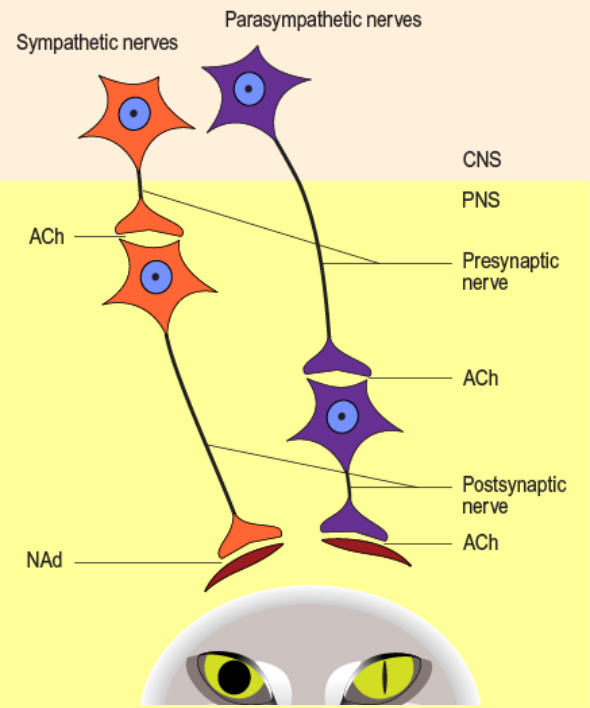

Fig 12.2 Thomson and Hahn,

Drug	Indirect acting (IA) Direct acting (DA)	Presynaptic nerve damage	Post synaptic nerve damage
Phenylephrine (1 or 10%) Adrenaline (0.001%)	DA sympathomimetic	Minimal effect	Mydriasis or change in eyelash angle due to denervation hypersensitivity
Hydroxyamphetamine (1%)	IA sympathomimetic triggers release of Ad at NMJ	Mydriasis	No effect
Pilocarpine 2%	DA parasympathomimetic	Minimal effect	Miosis due to denervation hypersensitivity
Physostigmine 0.5%	IA parasympathomimetic inhibits Achesterase at NMJ	Miosis	No effect

This alert cat, with normal gait, has no pupillary light reflex (PLR), and decreased vestibulo-ocular reflex (VOR), OD (right eye).
Lesion localisation is ...

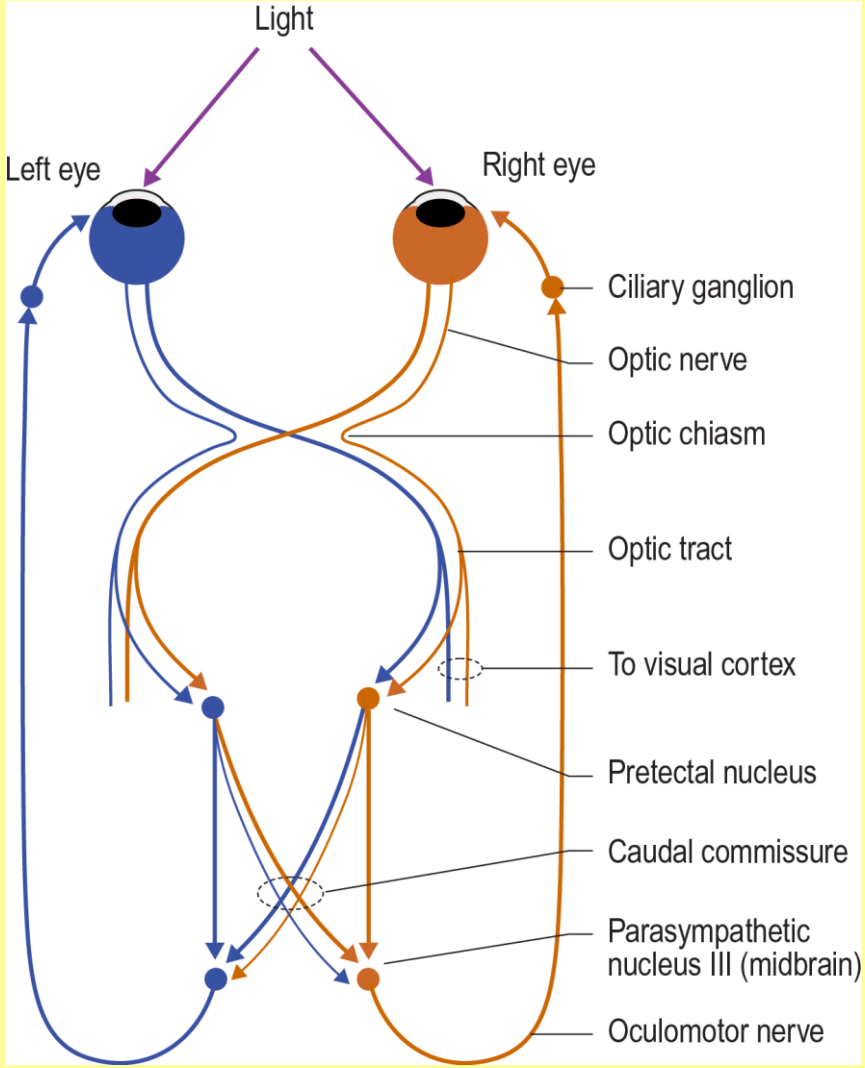

Image courtesy Dr. Susanne Anderson, NZ

Fig 10.8 Thomson and Hahn

Innervation of the Urinary Bladder

- Micturition
  - Primarily reflex function
  - Uses CPG
    - Maintains bladder contraction and sphincter relaxation
- Spinal cord
  - Spinoreticular and spinothalamic tracts
  - Reticulospinal tract
- Brainstem centres (pons)
  - UMN control
    - (spinoreticular activation)
    - (cerebrocortical activation)
- Cerebrum
  - Conscious awareness
  - Initiates learned toileting behaviour
- Cerebellum
  - Coordinates contraction-relaxation

Innervation of pelvic viscera

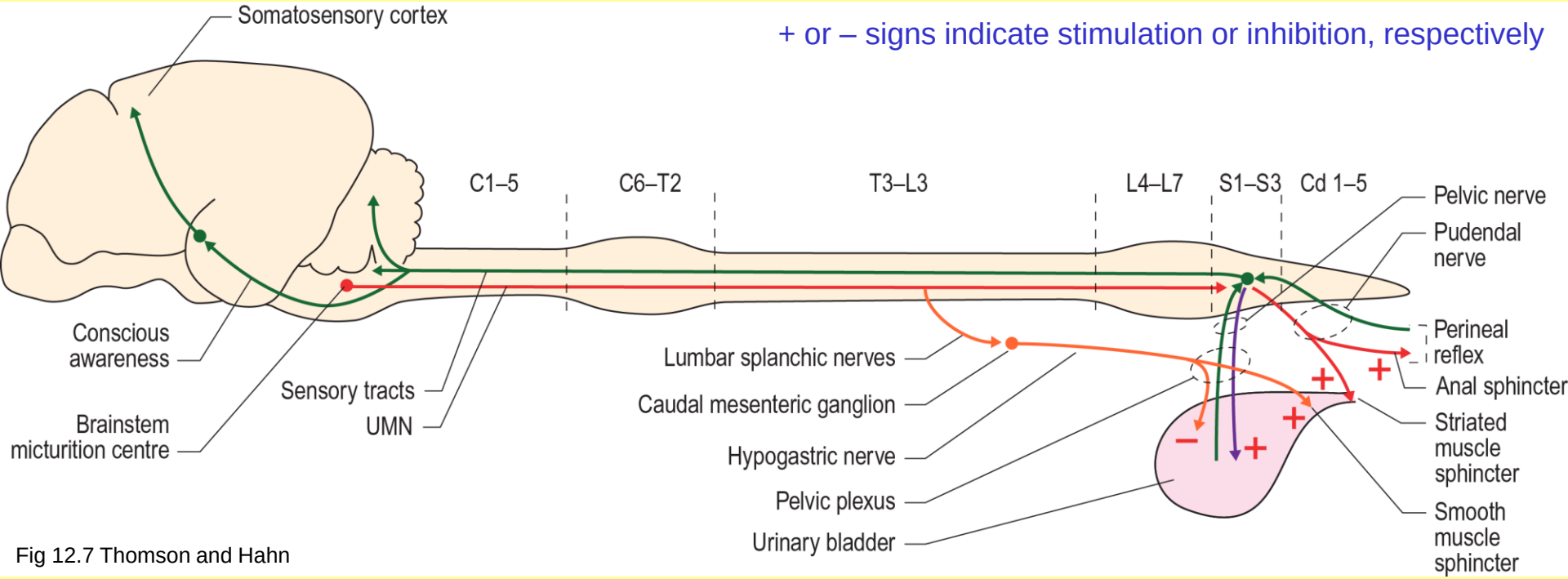

Fig 12.7 Thomson and Hahn

	Storage	Voiding
Parasympathetic	- detrusor relaxation	+ detrusor contraction
Sympathetic	+ β receptors bladder wall inhibition of detrusor + α bladder neck smooth muscle contracts	- β receptors in the bladder wall - α bladder neck muscle
Somatic	+ striated sphincter contracts	- striated sphincter relaxes

Incontinence (UMN or LMN)

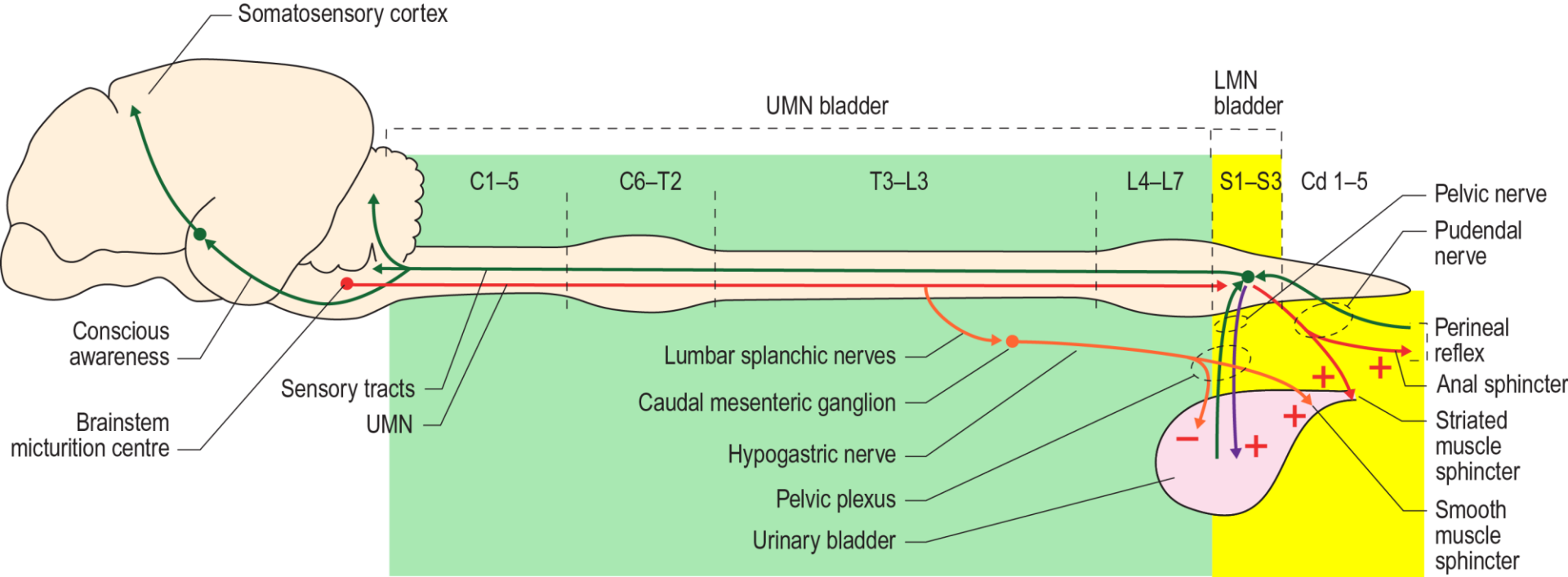

Figs 12.8 and 5.6, Thomson and Hahn

R – reflexes

A – atrophy

T – tone

Brain lesions

- Cerebral – loss of learned toileting behavior
- Cerebellar - ?

Pharmacological Rx urinary incontinence

target	innervation	drug
Striated sphincter relaxation	Somatic inhibition	Diazepam, dantrolene
Smooth muscle sphincter stimulation	Sympathetic alpha adrenergic stimulation	Phenylpropanolamine Oestrogen
Smooth muscle sphincter relaxation	Sympathetic alpha adrenergic inhibition	Phenoxybenzamine Prazosin HCl
Detrusor muscle stimulation	Parasympathetic	Bethanechol

Defaecation

- Primarily reflex
  - Local enteric plexus
  - Cranially directed paths for conscious perception
    - which funiculus?
  - Sphincters
    - Striated muscle
    - Smooth muscle

‘Puppy’

14 yo MN Gold Ret

Chronic incontinence – faecal and urinary

- Urinary bladder is…
- Anal sphincter is …
- Perineal reflex is …
- Sciatic reflexes…
- What else?

George, 7yo MN Siamese
3d Hx paraparesis
Acute urinary incontinence
- Urinary bladder is…
- Anal sphincter is …
- Perineal reflex is …