Anato-clinical correlation clinical cases

Chris Thomson
BVSc(Hons), Dip ACVIM (Neurol), Dip ECVN, PhD
Associate Professor Neurobiology,
Dept. of Vet. Med.,
University of Alaska, Fairbanks,
Alaska.

George: 7yo MN Siamese

Hx: 3 d paraparesis

Video observations

Puppy: 14yo MN GRet
Hx: chronic incontinence

Orlagh, 6yo XB FN
Hx 3d seizures, dropping food

Video observations

Bates: 4yo MN Springer Spaniel

- Hx:
- 2 week seizures (tonic-clonic)
- 3 days - lethargic

Video observations

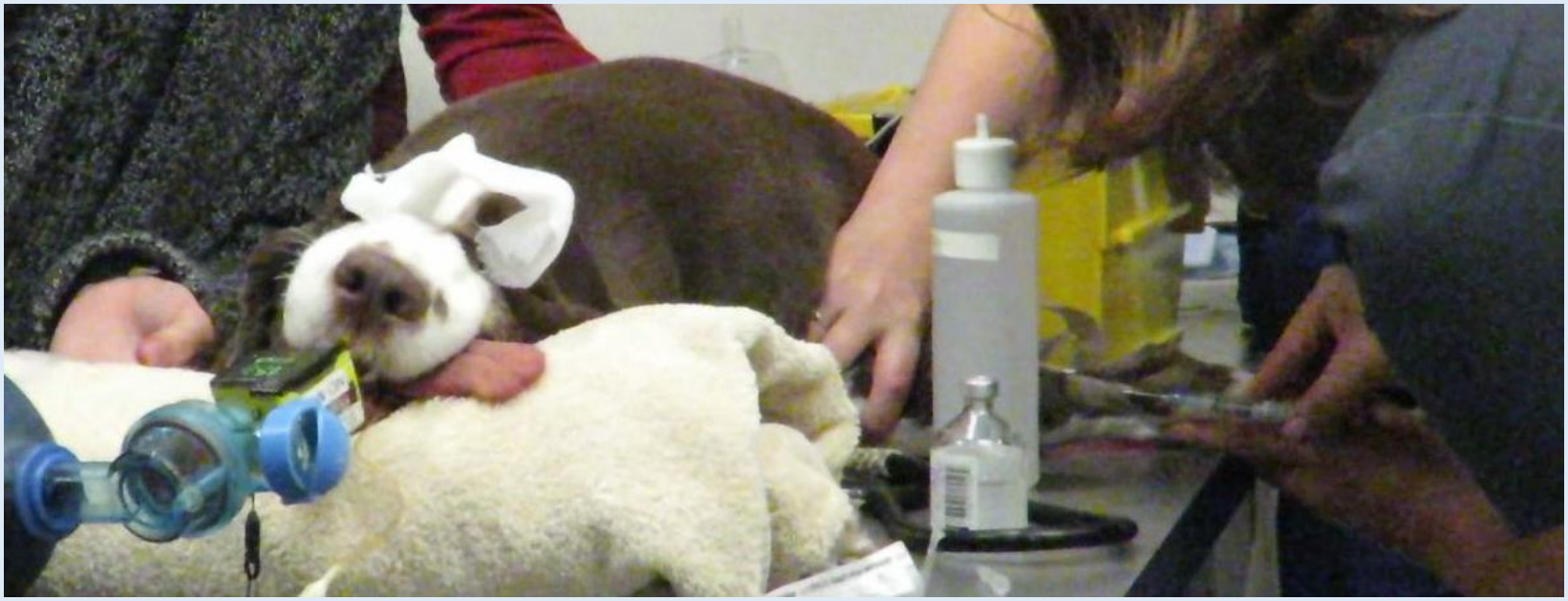

What reflexes can be used to check brainstem function?

Video observations

Nika: 5.5 yo FN Doberman X
Hx: 4 month mild non progressive lameness LTL
Ortho exam: No abnormalities
NEx: No abnormalities

Video observations

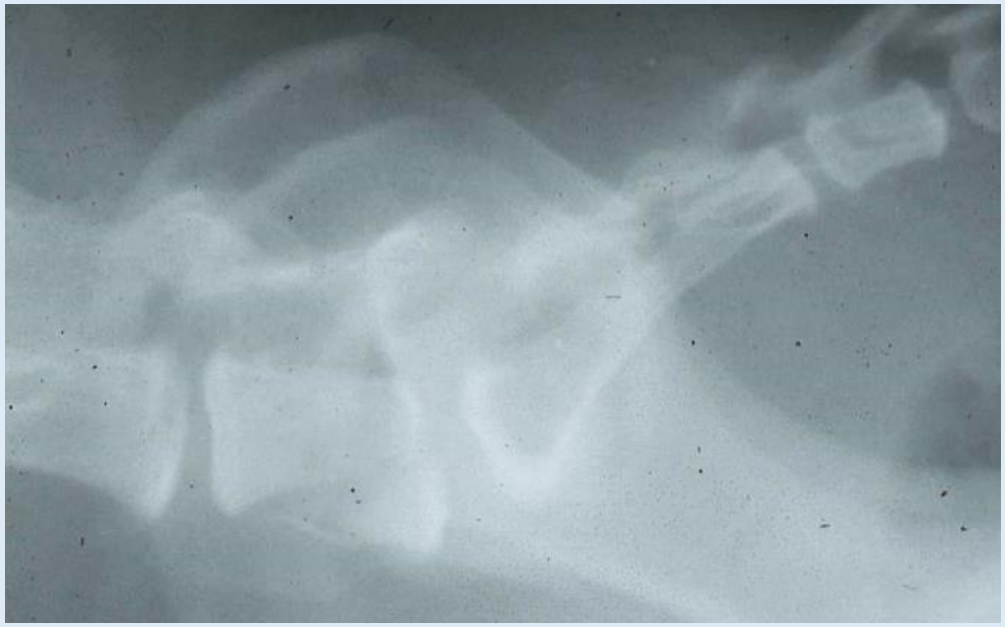

Gloucester,
9yo MN Beagle
Hx: road trauma 3 d ago
NEx: paraparetic
Intact PL reflexes

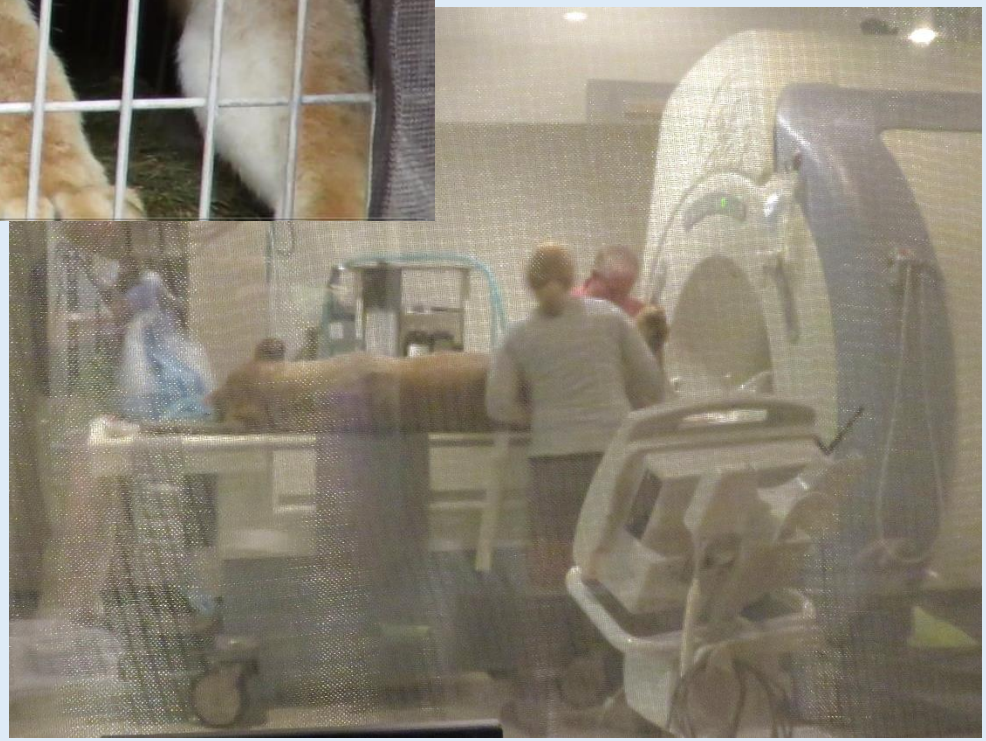

Leonie: 4yo lioness
Hx 3d paraparesis

How much of the NEx can you perform by observation?

Tundra: 4.5yo FN St Bernard
Hx: 6 wk progressive PL, then TL gait abnormality

Video observations

Left lateral recumbency
Shoulder muscle atrophy

Right lateral recumbency
Decreased shoulder flexion on pedal / withdrawal reflex

Battie: 7yo FN DSH
Hx: 3d walking in circles

Video observations

Beatrice: 1.5yo FN Burmese
Hx: abnormal gait

Video observations

Coryne: 10 yo DSH
Hx: 2 week walking in circles

Video observations

Sox: 5mo M, Heading dog
Hx 1 mo progressive gait deficit

Video observations

7 yo FN
Dachshund
Hx: 2d paraplegia

Harriet: 4.5yo FN
Fox terrier X
Hx: 3d progressive tetraparesis

Video observations

Normal handstand

‘Handstand’ to evaluate neck strength and vestibular function

Frankie: stray kitten
Hx: gait abnormality, faecal soiling

Video observations

Maypo: 10 yo MN DSH
Hx: 1 week walking in circles

Gilbert: 2yo MN Gt Dane,
Hx: chronic gait abnormality
LPL

Video observations